



# Radiosurgery Practice Guideline Initiative

## Stereotactic Radiosurgery for Patients with Intracranial Arteriovenous Malformations (AVM)

Practice Guideline Report #2-03

**ORIGINAL GUIDELINE: September 2003**

**MOST RECENT LITERATURE SEARCH: September 2003**

This practice guideline, together with a report on "Intracranial Arteriovenous Malformations (AVM): Overview" is an original guideline approved by the IRSA® (International RadioSurgery Association) Board of Directors and issued in September 2003.

### Preface

#### Summary

The IRSA® (International RadioSurgery Association) Radiosurgery Practice Guideline Initiative aims to improve outcomes for intracranial arteriovenous malformations by assisting physicians and clinicians in applying research evidence to clinical decisions while promoting the responsible use of health care resources.

#### Copyright

This guideline is copyrighted by IRSA (2003) and may not be reproduced without the written permission of IRSA. IRSA reserves the right to revoke copyright authorization at any time without reason.

#### Disclaimer

This guideline is not intended as a substitute for professional medical advice and does not address specific treatments or conditions for any patient. Those consulting this guideline are to seek qualified consultation utilizing information specific to their medical situation. Further, IRSA does not warrant any instrument or equipment nor make any representations concerning its fitness for use in any particular instance nor any other warranties whatsoever.

**KEY WORDS** • arteriovenous malformations • AVM • vascular malformation • stereotactic radiosurgery • Gamma Knife® • linear accelerator • proton beam • Bragg peak proton therapy • irradiation

### Consensus Statement

#### Objective

To develop a consensus-based radiosurgery practice guideline for treatment recommendations to be used by medical and public health professionals for patients with the diagnosis of brain or dural arteriovenous malformations (AVM).

#### Participants

The working group included nine physicians and one physicist, all of whom staff a major medical center that provides radiosurgery treatment.

#### Evidence

The first author(s) (LDL/AN) conducted a literature search in conjunction with the preparation of this document and development of other clinical guidelines. The literature identified was reviewed and opinions were sought from experts in the diagnosis and management of brain AVMs, including members of the working group.

#### Consensus Process

The initial draft of the consensus statement was a synthesis of research information obtained in the evidence-gathering process. Members of the working

group provided formal written comments that were incorporated into the preliminary draft of the statement. No significant disagreements existed. The final statement incorporates all relevant evidence obtained by the literature search in conjunction with final consensus recommendations supported by all working group members.

#### Group Composition

The Radiosurgery Guidelines Committee is comprised of neurological surgeons, radiation oncologists, and medical physicists. Community representatives did not participate in the development of this guideline.

*Names of Group Members:* L. Dade Lunsford, M.D., Neurosurgeon, Chair; Douglas Kondziolka, M.D., Neurosurgeon; Ajay Niranjana, M.B.B.S., M.Ch., Neurosurgeon; Christer Lindquist, M.D., Neurosurgeon; Jay Loeffler, M.D., Radiation Oncologist; Michael McDermott, M.D., Neurosurgeon; Michael Sisti, M.D., Neurosurgeon; John C. Flickinger, M.D., Radiation Oncologist; Ann Maitz, M.S., Medical Physicist; Michael Horowitz, M.D., Neurosurgeon and Interventional Radiologist; Tonya K. Ledbetter, M.S., M.F.S., Editor; Rebecca L. Emerick, M.S., M.B.A., C.P.A., ex officio.

## Conclusions

Specific recommendations are made regarding target population, treatment alternatives, interventions and practices and additional research needs. Appropriate use of radiosurgery in those with AVM following medical management may be beneficial.

This guideline is intended to provide the scientific foundation and initial framework for the person who has been diagnosed with a brain or dural arteriovenous malformation. The assessment and recommendations provided herein represent the best professional judgment of the working group at this time, based on research data and expertise currently available. The conclusions and recommendations will be regularly reassessed as new information becomes available.

## Stereotactic Radiosurgery

Brain stereotactic radiosurgery involves the use of precisely directed closed skull single fraction (one surgical session) radiation to create a desired radiobiologic response within the brain with minimal effects to surrounding structures or tissues. In the case of an arteriovenous malformation a relatively high dose of focused radiation is delivered precisely to the AVM, under the direct supervision of a radiosurgery team, in one surgical session. The irradiated vessels gradually occlude over a period of time. In Centers of Excellence, the radiosurgery team is composed of a neurosurgeon, radiation oncologist, physicist and registered nurse.

## Intracranial Arteriovenous Malformation: Overview

### Pathophysiology and Incidence

Intracranial arteriovenous malformations (AVM) constitute relatively rare and usually congenital vascular anomalies of the brain [1, 2]. AVMs are composed of complex connections between the arteries and veins that lack an intervening capillary bed. The arteries have a deficient muscularis layer. The draining veins often are dilated and tortuous due to the high velocity of blood flow through the fistulae. No genetic, demographic, or environmental risk factor has been associated with cerebral AVMs. Rarely inherited disorders, such as the Osler-Weber-Rendu syndrome (hereditary hemorrhagic telangiectasia), Sturge-Weber disease, neurofibromatosis, and von Hippel-Lindau syndrome are associated in a small minority of AVM patients. It is estimated that 10,000 to 12,000 new patients are diagnosed in the United States on an annual basis.

### Sex

Both sexes are affected equally.

### Age

Although AVMs are considered congenital, the clinical presentation most commonly occurs in young adults (20-40 years). Brain hemorrhage or seizure as an incident event may occur in young children or adults over 40. A history of subtle learning disorders is elicited in 66% of adults with AVMs

### Symptoms and Signs

AVM patients may present with brain hemorrhage, seizures, headache or progressive neurological deficit.

Many AVMs are identified because of the sudden onset of bleeding within the brain, which can be fatal or merely lead to serious headache with or without new neurological deficits. Deep-seated AVMs frequently present with hemorrhage. Hemorrhage may occur in the subarachnoid space, the intraventricular space or, most commonly, the brain parenchyma. The overall risk of intracranial hemorrhage in patients with known AVM is 2-4% per year. Specific angiographic features of the AVM increase the risk of hemorrhage. These include a small and only deep venous drainage, and relatively high arterial and venous pressures within the AVM nidus. Hemorrhage recurs in 15-20%, usually within the first year after the initial bleeding incident. Subcortical lobar AVMs may also present with seizures, progressive neurological deficits, or intractable vascular (migraine) headaches. Seizures occur as the presenting symptom in 25-50% of patients with AVM. These may be focal or secondary generalized seizures. Headache occurs in 10-50% of patients with AVM. Refractory headaches may be a presenting symptom if seizures or hemorrhages do not occur. The headache may be typical for migraine or may be present with a less specific complaint of more generalized head pain. Rarely, a progressive neurological deficit may occur over a few months to several years. The neurological deficits may be explained by the mass effect of an enlarging AVM or venous hypertension in the draining veins. In the absence of mass effect deficit could occur due to the siphoning of blood flow away from adjacent brain tissue (the "steal phenomenon").

### Imaging Studies

Patients are identified by high resolution neurodiagnostic imaging including CT and MRI scans supplemented by complete cerebral angiography. High-quality MRI is essential for initial diagnosis of AVMs. AVMs appear as irregular or globoid masses anywhere within the hemispheres or brain stem. AVMs may be cortical, subcortical, or in deep gray or white matter. Small, round, low-signal spots within or around the mass on T1, T2, or fluid-attenuated inversion recovery (FLAIR) sequences are the "flow voids" of feeding arteries, intranidal aneurysms, or draining veins. If hemorrhage has occurred, the hematoma may obscure other diagnostic features, requiring angiogram or follow-up MRI. Dark signal of extracellular hemosiderin may be seen around or within the AVM mass, indicating prior hemorrhage. Aneurysms within the AVM or on feeding arteries may be identified occasionally.

Cerebral angiography is required to assess morphology and hemodynamics, which are essential for planning treatment. Important features include feeding arteries, venous drainage pattern, and arterial and venous aneurysms. Ten to fifty-eight percent of patients with AVM have aneurysms located in vessels remote from the AVM, in arteries feeding the AVM, or within the nidus of the AVM itself. Intranidal aneurysms may have a higher risk of rupture than those outside the bounds of the AVM.

### Management

Once identified, arteriovenous malformations may be suitable for one or more of four management strategies: observation, surgical excision, stereotactic radiosurgery or endovascular embolization [3]. AVM management depends on risk of subsequent hemorrhage, which is determined by the anatomical (MRI and angiography), historical, and demographic features of the individual patient. Young age, prior hemorrhage, small AVM size, deep venous drainage, and high flow makes subsequent hemorrhage more likely.

Observation may be most appropriate for large volume AVMs (average diameter 4-5 cm), especially for patients who have never bled. Studies of the natural history of AVMs suggest an annual hemorrhage rate of 2-4% with an annual 1% mortality rate from AVM bleeding. A second strategy is endovascular embolization, which is often used as an adjunct preceding surgical removal of the AVM via craniotomy and at times before stereotactic radiosurgery. Other vascular anomalies may be associated with AVMs including the presence of proximal intracranial or intranidal aneurysms. Such aneurysms may pose additional risk factors to patients. Surgical management options are not part of this discussion, although incomplete surgical obliteration may prompt eventual radiosurgery. Embolization prior to radiosurgery is thought to be beneficial in some cases, but in other cases may lead to less reliable recognition of the target volume suitable for radiosurgery [4]. Re-canalization of embolized AVM components may require subsequent re-treatment for portions of the AVM previously thought to be occluded by successful embolization.

Stereotactic radiosurgery is considered for patients with unresectable AVMs. Such patients may warrant treatment based on age, location, volume, or medical history. Radiation technologies for stereotactic radiosurgery include Gamma Knife® radiosurgery, proton beam radiosurgery, and linear accelerators (LINACs) modified at Centers of Excellence with extensive AVM experience [5-26]. Multi-modality management teams are essential for proper patient selection and patient care. Because of the delayed obliteration rate of AVMs after radiosurgery, comprehensive long-term management and observational strategies are necessary. Patients usually receive a single dose (40 mg) of methylprednisolone at the conclusion of the radiosurgery procedure. They can continue to take their other medications (antiepileptics, analgesics, etc.) after the procedure as recommended by their physicians. Postradiosurgical clinical examinations and MR studies are requested at six month intervals for the first three years to assess the effect of radiosurgery on AVM (gradual obliteration). If MRI at the three-year mark suggests complete closure of the AVM nidus, an angiogram is obtained to confirm the obliteration. If the MR imaging before three years suggests nidus obliteration, angiography is generally delayed until three

full years have elapsed. If angiography after three years demonstrates that the AVM nidus is not obliterated, repeat stereotactic radiosurgery is recommended [27, 28].

Dose volume guidelines for AVM management have been extensively published [29-32]. AVM outcomes are best for those patients with small volume AVMs located in non-critical locations [21, 33-36]. Children may respond faster than adults in terms of the obliteration rate. Obliteration is a process resulting from endothelial proliferation within the AVM blood vessel walls, supplemented by myofibroblast proliferation. This leads to contraction and eventual obliteration of the AVM blood vessels [37-39]. The process is cumulative, with earliest obliterations noted within two to three months, 50% of the effect often seen within one year, 80% within two years, and 90% within three years. If at the end of three years residual AVM is identified by imaging, repeat radiosurgery may be considered (as may other management strategies designed to complete obliteration of the AVM) [21, 33-36].

Average marginal dose depends upon the technology used. Commonly, the 50-70% isodose is used for photon radiosurgery, and different doses are used for particle beam radiosurgery using protons [29-31, 40]. Conformal radiosurgery is required in order to maximize dose within the three-dimensionally defined AVM volume while restricting dose to the surrounding brain.

Current studies indicate a success rate between 50-95% at the end of three years of observation after a single radiosurgery procedure [5-26]. The long-term result of radiosurgery (5-14 year results after Gamma Knife® radiosurgery) suggest that the majority of AVM patients (73%) are protected from the risk of future hemorrhage and continue their normal daily activities after radiosurgery [41]. The identification of a patient with brain or dural AVMs suitable for radiosurgery requires a commitment to long-term follow-up care and a team management strategy using the talents of neurological surgeons, radiation oncologists, neuro-imaging specialists, and medical physicists. Additional management strategies include surgery, embolization, and radiosurgery alone or in combination [42-46].

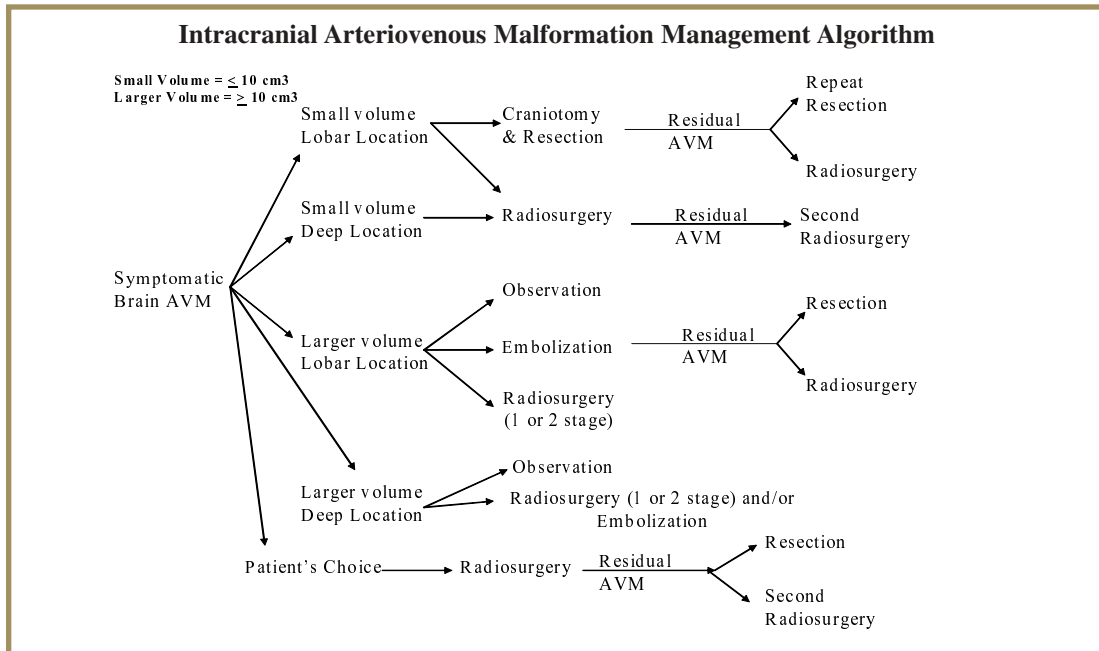
## CLINICAL ALGORITHM

A number of factors are considered in making a recommendation. These factors include:

1. Patient's age
2. Patient's medical condition
3. Previous bleed
4. Prior procedures
5. Volume of AVM

6. Location of AVM
7. Presenting symptoms

A broad outline of management algorithm is shown below; however, the final recommendation is usually influenced by the recommending neurosurgeon's experience along with patient preference.



### References

1. Stein, B.M. and S.M. Wolpert, Arteriovenous malformations of the brain. I: Current concepts and treatment. Archives of Neurology, 1980. 37(1): p. 1-5.
2. Wilkins, R.H., Natural history of intracranial vascular malformations: a review. Neurosurgery, 1985. 16(3): p. 421-30.
3. Smith, J.L. and B. Garg, Treatment of arteriovenous malformations of the brain. Current Neurology & Neuroscience Reports, 2002. 2(1): p. 44-9.
4. Pollock, B.E., et al., Embolization and radiosurgery for AVMs.[comment]. Journal of Neurosurgery, 1997. 86(2): p. 319-20; author reply 320-1.
5. Crocco, A., Arteriovenous malformations in the basal ganglia region: Gamma Knife radiosurgery as first choice treatment in selected cases. Journal of Neurosurgical Sciences, 2002. 46(2): p. 43-54.
6. Ellis, T.L., et al., Analysis of treatment failure after radiosurgery for arteriovenous malformations. Journal of Neurosurgery, 1998. 89(1): p. 104-10.
7. Flickinger, J.C., et al., Radiosurgical management of intracranial vascular malformations. Neuroimaging Clinics of North America, 1998. 8(2): p. 483-92.
8. Friedman, W.A., Radiosurgery for arteriovenous malformations. Clinical Neurosurgery, 1995. 42: p. 328-47.
9. Hadjipanayis, C.G., et al., Stereotactic radiosurgery for motor cortex region arteriovenous malformations. Neurosurgery, 2001. 48(1): p. 70-6; discussion 76-7.
10. Karlsson, B., C. Lindquist, and L. Steiner, Prediction of obliteration after gamma knife surgery for cerebral arteriovenous malformations. Neurosurgery, 1997. 40(3): p. 425-30; discussion 430-1.
11. Kobayashi, T., et al., Gamma knife treatment of AVM of the basal ganglia and thalamus. No to Shinkei - Brain & Nerve, 1996. 48(4): p. 351-6.
12. Kondziolka, D. and L.D. Lunsford, The case for and against AVM radiosurgery. Clinical Neurosurgery, 2001. 48: p. 96-110.
13. Kurita, H., et al., Results of radiosurgery for brain stem arteriovenous malformations. [comment]. Journal of Neurology, Neurosurgery & Psychiatry, 2000. 68(5): p. 563-70.
14. Levy, E.I., et al., Radiosurgery for childhood intracranial arteriovenous malformations. Neurosurgery, 2000. 47(4): p. 834-41; discussion 841-2.
15. Maesawa, S., et al., Repeated radiosurgery for incompletely obliterated arteriovenous malformations. Journal of Neurosurgery, 2000. 92(6): p. 961-70.
16. Massager, N., et al., Gamma knife radiosurgery for brainstem arteriovenous malformations: preliminary results. Journal of Neurosurgery, 2000. 93 Suppl 3: p. 102-3.
17. Miyawaki, L., et al., Five year results of LINAC radiosurgery for arteriovenous malformations: outcome for large AVMs. International Journal of Radiation Oncology, Biology, Physics, 1999. 44(5): p. 1089-106.
18. Nakanishi, A., et al., Linac-based stereotactic radiosurgery for arteriovenous malformations (AVMs) in brain: estimation for efficacy of therapeutic response using angiography. Nippon Igaku Hoshasen Gakkai Zasshi - Nippon Acta Radiologica, 1999. 59(4): p. 137-42.
19. Nicolato, A., et al., Stereotactic radiosurgery for the treatment of arteriovenous malformations in



- childhood. *Journal of Neurosurgical Sciences*, 1997. 41(4): p. 359-71.
20. Pan, D.H., et al., Gamma knife radiosurgery as a single treatment modality for large cerebral arteriovenous malformations. *Journal of Neurosurgery*, 2000. 93 Suppl 3: p. 113-9.
  21. Pollock, B.E., et al., Factors associated with successful arteriovenous malformation radiosurgery. *Neurosurgery*, 1998. 42(6): p. 1239-44; discussion 1244-7.
  22. Pollock, B.E., Stereotactic radiosurgery for arteriovenous malformations. *Neurosurgery Clinics of North America*, 1999. 10(2): p. 281-90.
  23. Ross, D.A., et al., Stereotactic radiosurgery of cerebral arteriovenous malformations with a multileaf collimator and a single isocenter. *Neurosurgery*, 2000. 47(1): p. 123-8; discussion 128-30.
  24. Schlienger, M., et al., Linac radiosurgery for cerebral arteriovenous malformations: results in 169 patients. *International Journal of Radiation Oncology, Biology, Physics*, 2000. 46(5): p. 1135-42.
  25. Shin, M., et al., Retrospective analysis of a 10-year experience of stereotactic radio surgery for arteriovenous malformations in children and adolescents.[comment]. *Journal of Neurosurgery*, 2002. 97(4): p. 779-84.
  26. Young, C., et al., Radiosurgery for arteriovenous malformations: the University of Toronto experience. *Canadian Journal of Neurological Sciences*, 1997. 24(2): p. 99-105.
  27. Lunsford, L.D., et al., Black holes, white dwarfs and supernovas: imaging after radiosurgery. *Stereotactic & Functional Neurosurgery*, 1998. 70 Suppl 1: p. 2-10.
  28. Kihlstrom, L., et al., Magnetic resonance imaging of obliterated arteriovenous malformations up to 23 years after radiosurgery.[comment]. *Journal of Neurosurgery*, 1997. 86(4): p. 589-93.
  29. Flickinger, J.C., et al., A dose-response analysis of arteriovenous malformation obliteration after radiosurgery.[comment]. *International Journal of Radiation Oncology, Biology, Physics*, 1996. 36(4): p. 873-9.
  30. Flickinger, J.C., D. Kondziolka, and L.D. Lunsford, Dose selection in stereotactic radiosurgery. *Neurosurgery Clinics of North America*, 1999. 10(2): p. 271-80.
  31. Flickinger, J.C., et al., An analysis of the dose-response for arteriovenous malformation radiosurgery and other factors affecting obliteration. *Radiotherapy & Oncology*, 2002. 63(3): p. 347-54.
  32. Mavroidis, P., et al., Prediction of AVM obliteration after stereotactic radiotherapy using radiobiological modeling. *Physics in Medicine & Biology*, 2002. 47(14): p. 2471-94.
  33. Pollock, B.E., et al., Repeat stereotactic radiosurgery of arteriovenous malformations: factors associated with incomplete obliteration. *Neurosurgery*, 1996. 38(2): p. 318-24.
  34. Kwon, Y., et al., Analysis of the causes of treatment failure in gamma knife radiosurgery for intracranial arteriovenous malformations. *Journal of Neurosurgery*, 2000. 93 Suppl 3: p. 104-6.
  35. Friedman, W.A., et al., Analysis of factors predictive of success or complications in arteriovenous malformation radiosurgery. *Neurosurgery*, 2003. 52(2): p. 296-307; discussion 307-8.
  36. Chang, J.H., et al., Factors related to complete occlusion of arteriovenous malformations after Gamma Knife radiosurgery. *Journal of Neurosurgery*, 2000. 93 Suppl 3: p. 96-101.
  37. Chang, S.D., et al., Stereotactic radiosurgery of arteriovenous malformations: pathologic changes in resected tissue. *Clinical Neuropathology*, 1997. 16(2): p. 111-6.
  38. Szeifert, G.T., Radiosurgery and AVM histopathology.[comment]. *Journal of Neurosurgery*, 1998. 88(2): p. 356-7.
  39. Schneider, B.F., D.A. Eberhard, and L.E. Steiner, Histopathology of arteriovenous malformations after gamma knife radiosurgery.[comment]. *Journal of Neurosurgery*, 1997. 87(3): p. 352-7.
  40. Flickinger, J.C., et al., Complications from arteriovenous malformation radiosurgery: multivariate analysis and risk modeling. *International Journal of Radiation Oncology, Biology, Physics*, 1997. 38(3): p. 485-90.
  41. Pollock, B. E., Gorman, D. A., Coffey, R. J, Patient outcomes after arteriovenous malformation radiosurgical management: results based on a 5- to 14-year follow-up study. *Neurosurgery*. 2003.52:1291-6.
  42. Jizong, Z., et al., Combination of intraoperative embolisation with surgical resection for treatment of giant cerebral arteriovenous malformations. *Journal of Clinical Neuroscience*, 2000. 7 Suppl 1: p. 54-9.
  43. Martin, N.A., et al., Therapeutic embolization of arteriovenous malformations: the case for and against. *Clinical Neurosurgery*, 2000. 46: p. 295-318.
  44. Negoro, M., et al., Recent advances in AVM embolization. *No to Shinkei - Brain & Nerve*, 2000. 52(7): p. 565-9.
  45. Tokunaga, K., et al., Curative treatment of cerebral arteriovenous malformations by embolisation using cellulose acetate polymer followed by surgical resection. *Journal of Clinical Neuroscience*, 2000. 7 Suppl 1: p. 1-5.
  46. Miyachi, S., et al., Embolisation of cerebral arteriovenous malformations to assure successful subsequent radiosurgery. *Journal of Clinical Neuroscience*, 2000. 7 Suppl 1: p. 82-5.

## COMPLETE SUMMARY

**TITLE:**

Stereotactic radiosurgery for patients with intracranial arteriovenous malformations (AVM)

**RELEASE DATE:**

September 2003

**DEVELOPER AND FUNDING SOURCE:**

IRSA (International RadioSurgery Association)

**DEVELOPER COMMENT:**

IRSA (International RadioSurgery Association) is a non-profit entity dedicated to promoting the development of scientifically relevant practice guidelines for stereotactic radiosurgery. IRSA is a professional organization that works to educate and provide support for physicians, hospitals, insurers, and patients.

**COMMITTEE:**

The IRSA Medical Advisory Board Guidelines Committee and representatives in the industry

**GROUP COMPOSITION:**

The Radiosurgery Guidelines Committee is comprised of neurological surgeons, radiation oncologists, and medical physicists.

*Names of Group Members:* L. Dade Lunsford, M.D., Neurosurgeon, Chair; Douglas Kondziolka, M.D., Neurosurgeon; Ajay Niranjana, M.B.B.S., M.Ch., Neurosurgeon; Christer Lindquist, M.D., Neurosurgeon, European Co-Chair; Jay Loeffler, M.D., Radiation Oncologist; Michael McDermott, M.D., Neurosurgeon; Michael Sisti, M.D., Neurosurgeon; John C. Flickinger, M.D., Radiation Oncologist; Ann Maitz, M.S., Medical Physicist; Michael Horowitz, M.D., Neurosurgeon and Interventional Radiologist; Tonya K. Ledbetter, M.S., M.F.S., Editor; Rebecca L. Emerick, M.S., M.B.A., C.P.A., ex officio.

**DISEASE/CONDITION:**

Arteriovenous malformations (AVM), brain (cerebrum, cerebellum, dura)

**NUMBER OF REFERENCES:**

46

**CATEGORY:**

Treatment, proposed surgical management

**CLINICAL SPECIALTY:**

Neurological surgery  
Neurology  
Radiation oncology

**INTENDED USERS:**

Physicians  
Health Care Providers  
Hospitals  
Managed Care Organizations  
Nurses  
Utilization Management

**OBJECTIVES:**

To develop an evidenced and consensus-based stereotactic radiosurgery practice guideline for symptomatic patients with imaging identified arteriovenous malformations of the brain for treatment recommendations to be used by medical and public health professionals. Such patients may or may not be candidates for alternative management strategies that include observation, surgical resection via craniotomy, and endovascular embolization.

**TARGET POPULATION:**

Men and women >2 years old with imaging identified congenital or acquired arteriovenous malformations of the brain, including the cerebrum, cerebellum, brainstem and dura. Patients often are not considered candidates for surgical resection based on size or anatomic location, or medical co-morbidities and advanced age.

**INTERVENTIONS AND PRACTICES:**

Stereotactic radiosurgery of cerebral arteriovenous malformations is performed using single procedure or occasionally staged procedure techniques based on intraoperative stereotactic guidance, digitally acquired images (CT or MRI) and intracranial angiography.

Dose selection to the arteriovenous malformation is related to AVM volume, location, and a predicted obliteration rate within three years, as well as a reasonably estimated adverse radiation risk to surrounding brain. Minimal AVM doses in a single treatment vary from 16 to 25 Gy, with volumetric conformal radiosurgery designed to provide maximal dose sparing to surrounding brain tissue.

**OUTCOMES CONSIDERED:**

Total obliteration of the arteriovenous malformation within three years is the primary end point of interest. Additional outcome end points include resolution or an improvement in seizure disorders if present, resolution or reduction in vascular headache syndromes, and prevention of bleeding risks from the arteriovenous malformation (estimated to vary between 1-10% per year depending upon prior bleeding history, location, and volume). Improvement in the existing neurological deficits is also considered. Maintenance of quality of life, employability, and prevention of adverse radiation effects are also considered.

**METHODS TO COLLECT EVIDENCE:**

Hand Searches of Published Literature (Primary Sources); Hand Searches of Published Literature (Secondary Sources); Searches of Electronic Databases

**DESCRIPTION OF METHODS TO COLLECT EVIDENCE:**

MEDLINE and PUBMED searches were completed for the years 1971 to September 2003. Search terms included arteriovenous malformation, AVM, vascular malformation, stereotactic radiosurgery, Gamma Knife®, irradiation, Linac radiosurgery, proton beam radiosurgery, Bragg peak proton therapy, clinical trials, research design, practice guidelines and meta-analysis. Bibliographies from recently published reviews were reviewed and relevant articles were retrieved.

**METHODS TO ASSESS THE QUALITY AND STRENGTH OF THE EVIDENCE:**

Expert consensus (committee)

**METHODS TO ANALYZE EVIDENCE:**

Review of published meta-analysis

**REVIEW METHODS:**

External peer review; internal peer review

**DESCRIPTION OF REVIEW METHODS:**

The recommendations were originally suggested by a core group of four members. These recommendations were mailed to all committee members. Feedback was obtained through this mailed survey in order to revise the proposed guidelines. Committee members were asked whether the recommendations should serve as a practice guideline. No significant disagreements existed. The final statement incorporates all relevant evidence obtained by the literature search in conjunction with the final consensus recommendations supported by all working group members.

**MAJOR RECOMMENDATIONS:**

- Patients with intracranial arteriovenous malformations defined by modern neurodiagnostic imaging including CT, MRI scan, and cerebral

angiography constitute the study group. Such patients typically present with brain hemorrhage (especially when located in deep anatomic locations of the brain), persistent seizures, vascular headache syndrome or progressive neurological deficits. Arteriovenous malformations are considered suitable for four management strategies alone or in combination: observation only, surgical excision, endovascular embolization (designed to reduce either a selected volume or flow through the AVM), and stereotactic radiosurgery. Stereotactic radiosurgery is typically employed alone but also may be employed in combination with prior surgery or embolization in particular circumstances. Size ranges of average diameter are usually less than 3 cm (0.1-10 cm<sup>3</sup>). Prospective stereotactic radiosurgery volumetric staging is frequently performed for those symptomatic patients with AVM volumes > 15 cm<sup>3</sup> in the absence of other acceptable risk management strategies and can be considered for AVMs between 10-15 cm<sup>3</sup>. The selection of patients suitable for radiosurgery is dependent on the prior bleeding history, the age of the patient, existing co-morbidities, anatomic location, and clinical history. Radiosurgery, a minimally invasive closed skull treatment strategy, may be especially suitable for patients in advanced age groups or those with excessive medical co-morbidity risk factors for surgical excision.

- The optimal dose range for volumetric conformal stereotactic AVM radiosurgery has been largely established based on location and volume of the AVM. Doses at the margin of the AVM typically range from 16-25 Gy in a single fraction, wherein the volume of the AVM is defined by stereotactic guidance during the procedure itself. Stereotactic volumetric axial plane imaging (MRI or CT) supplemented by conventional or digital subtraction angiography is usually necessary for complete conformal dose planning. Dose selection depends on location, volume, estimated adverse radiation risks, pre-existing neurological conditions, and prior bleeding history. Depending upon the technology used, the margin of the AVM dose is usually 50-70% of the central target dose within the AVM. Sharp fall-off of the radiation dose outside of the target volume is required. Current radiation delivery technologies for volumetric stereotactic conformal single fraction radiosurgery include Gamma Knife®, proton beam using Bragg peak effect, and specially modified linear accelerators.
- Patients usually receive a single dose (40 mg) of methylprednisolone at the conclusion of the radiosurgery procedure. They can continue to take their other medications (antiepileptics, analgesics, etc.) during and after the procedure as recommended by their physicians.
- Some AVM patients will have been previously treated by embolization for volumetric reduction or flow reduction. Some patients may have had prior intracranial surgery for blood clot (hematoma) evacuation or partial AVM resection. The safe interval between surgery and stereotactic radiosurgery is not known, but it is reasonable to perform radiosurgery once the patient has achieved

a stable neurological recovery or plateau (generally within two to three months after the intracranial hemorrhage or prior surgery). The optimal time between prior embolization and radiosurgery is not known, but generally waiting for a period of several weeks is considered beneficial in order to reduce the likelihood of vascular ischemic complications or residual cerebral edema sometimes associated with embolization followed by early radiosurgery.

- Postradiosurgical clinical examinations and MR studies are requested by referring physicians at six month intervals for the first three years to assess the effect of radiosurgery on AVM (gradual obliteration). If MR at the three-year mark suggests complete disappearance of the AVM nidus, an angiogram is obtained to confirm the obliteration. If the MR imaging before three years suggests nidus obliteration, angiography is generally delayed until three full years have elapsed. If angiography after three years demonstrates that the AVM nidus is not obliterated, repeat stereotactic radiosurgery is recommended.
- Patients who have residual arteriovenous malformations identified by neurodiagnostic imaging at three years (after radiosurgery) may be candidates for a second stereotactic radiosurgical procedure. Alternatively, patients with larger volume AVMs (e.g., >10 cm<sup>3</sup>) may be considered suitable for up-front volumetric staging of AVMs by treating different anatomic components of the AVM at intervals staged between three and six months. The interval for staging of radiosurgery prospectively is not established. Stereotactic radiosurgery should not be considered as the panacea for large volume AVMs unsuitable for surgery or embolization. At selected centers with experience, estimated obliteration rates after two radiosurgical procedures at five years approach 60-70%. For smaller volume AVMs (average diameters < 3 cm<sup>3</sup>), estimated complete obliteration rates at three years after a single procedure vary from 70-90%.
- Causes for failure of stereotactic radiosurgery have been identified and include inadequate visualization of the target nidus, lack of intraoperative stereotactic 3-D (volumetric axial plane imaging), insufficient dose to achieve the oblitative response, compression of the AVM nidus by a prior hematoma, or poor nidus visualization secondary to overlying vascular structures. In a few cases selected radiobiological resistance of undetermined etiology may be the cause of obliteration failure.
- At present, technologies delivered to provide volumetric stereotactic radiosurgery are limited to Gamma Knife®, modified linear accelerators at centers supplemented by significant experience, and proton beam facilities in the United States.
- Stereotactic radiosurgery is defined as a relatively high dose of focused radiation delivered precisely to the malformation, under the direct supervision of a medical team (neurosurgeon, radiation oncologist, registered nurse, and medical physicist), in one surgical treatment session

**TYPE OF EVIDENCE:**

Type I, II and III evidence (Bandolier) exists in support of stereotactic radiosurgery for arteriovenous malformations.

**POTENTIAL BENEFITS:**

All the published studies have shown a significant response of stereotactic radiosurgery for arteriovenous malformations including a high rate of AVM nidus obliteration, concomitant improvement in seizure control, headache resolution, and a satisfactory (low) rate of adverse radiation effect that might lead to additional neurological deficits. Complete obliteration of the AVM is considered necessary in order to definitely eliminate the risk of future bleeding. To date, insufficient evidence exists to establish whether bleeding rates are reduced more than five years after AVM radiosurgery even in patients who have had incomplete obliteration. Successful outcomes include complete AVM obliteration, symptomatic relief, no new neurological deficits, no long term complications, and life-long prevention of bleeding risks.

Literature has documented the cost savings benefit of stereotactic radiosurgery versus invasive surgical procedures and the lower risk potential of bleeding from surgical incisions, anesthesia problems, infections and side effects which may include transient or permanent disabilities from open surgery.

**SUBGROUP(S) MOST LIKELY TO BENEFIT:**

Patients with brain or dural arteriovenous malformations considered unsuitable for complete excision by surgical craniotomy or complete obliteration by endovascular embolization.

**POTENTIAL HARMS:**

Major adverse effects of radiosurgery are based on location, volume, dose, and flow, and these risks can be estimated based on published data and experience. Individual risks are related to the anatomical location of the AVM. Currently, the estimated adverse risk of

permanent new neurological deficits related to radiation in a large group of patients undergoing radiosurgery is 3-5%. Late delayed potential risks of radiosurgery should be assessed by MRI at five and ten years after obliteration is confirmed.

**SUBGROUP(S) LIKELY TO BE HARMED:**

Patients with large volume AVMs who are treated with large doses in a single fraction, especially if the AVM is located in a deep brain area. Patients with large AVMs in a deep brain area, in whom the risk of bleeding over their expected lifetime is less than the risk of radiosurgery complications, will benefit least from radiosurgery.

**GUIDELINE STATUS:**

This is the full current release of the guideline

**GUIDELINE AVAILABILITY:**

Electronic copies: Available in Portable Document Format (PDF) from [www.IRSA.org](http://www.IRSA.org)

Print copies: Available from IRSA, 3005 Hoffman Street, Harrisburg, PA 17110

**PATIENT RESOURCES:**

Patient resources are available on line at [www.IRSA.org](http://www.IRSA.org), by email at [intouch@IRSA.org](mailto:intouch@IRSA.org) or by calling +717-260-9808.

See "publications" for patient resources for arteriovenous malformations: [www.IRSA.org/publications.html/](http://www.IRSA.org/publications.html/) *Brain Talk*® Volume 8, No. 1; Volume 6, No. 1; *Another Perspective*® Volume 4, No. 3; Volume 4, No. 2 *Brochure on AVMs available by mail.*

**COPYRIGHT STATEMENT:**

Copyright IRSA 2003